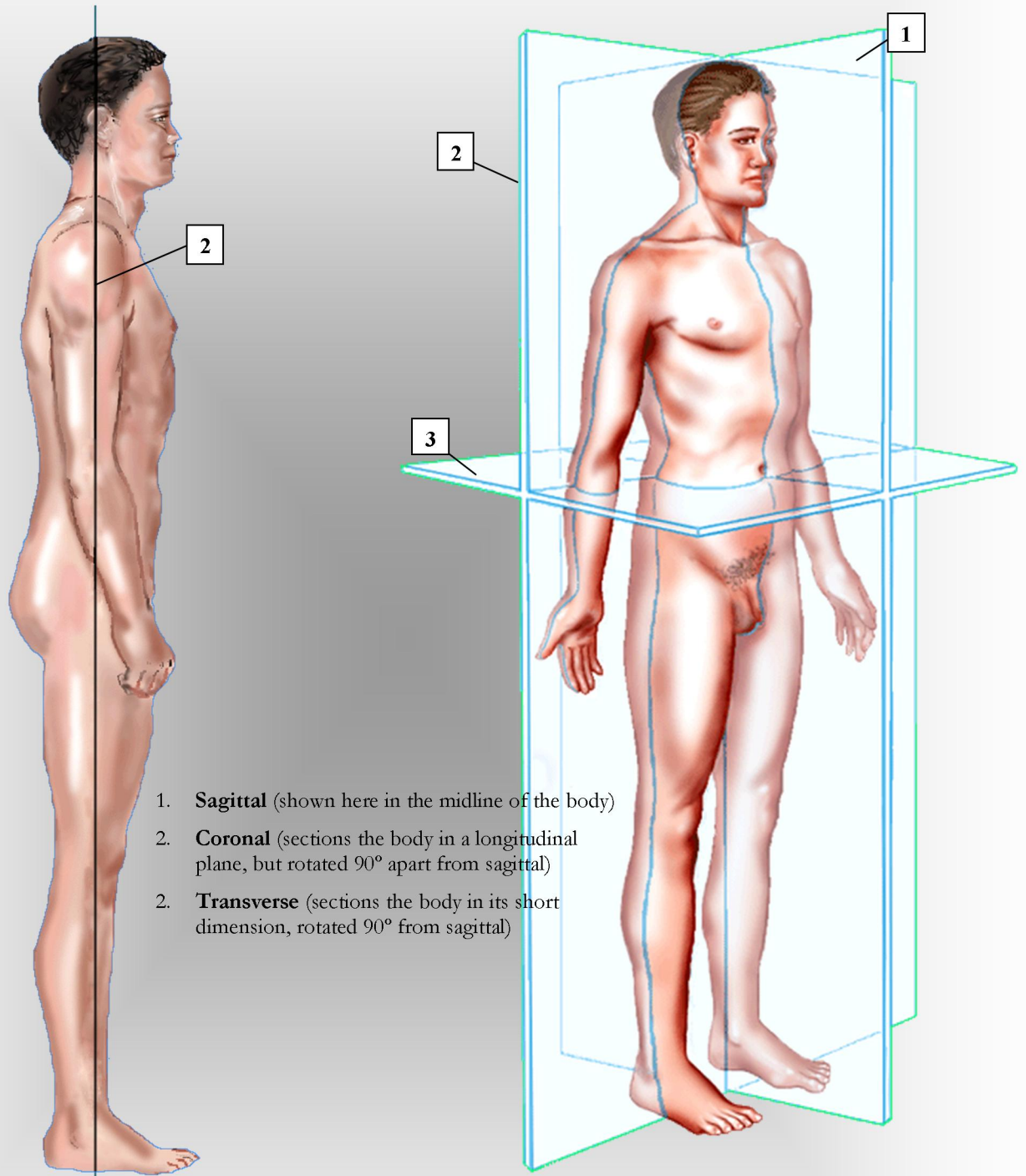


SOMATIC REFERENCE PLANES



1. **Sagittal** (shown here in the midline of the body)
2. **Coronal** (sections the body in a longitudinal plane, but rotated 90° apart from sagittal)
2. **Transverse** (sections the body in its short dimension, rotated 90° from sagittal)