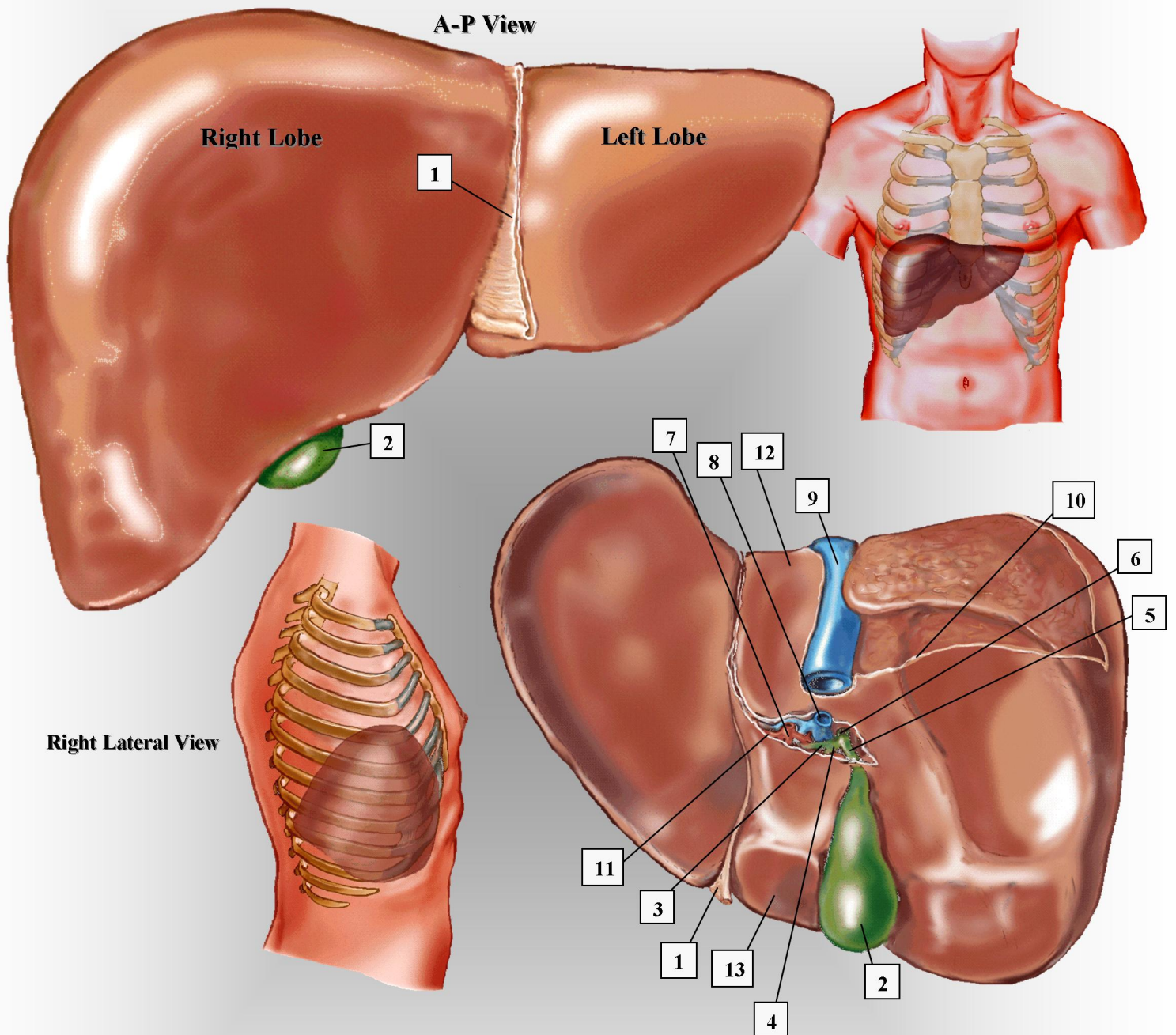


THE LIVER



- | | | |
|------------------------------------|---------------------|-----------------------------|
| 1. falciform ligament | 5. cystic duct | 9. inferior vena cava (IVC) |
| 2. gallbladder | 6. common bile duct | 10. fibrous hepatic capsule |
| 3. right & left intrahepatic ducts | 7. hepatic artery | 11. porta hepatis |
| 4. common hepatic duct | 8. main portal vein | 12. caudate lobe |
| | | 13. quadrate lobe |