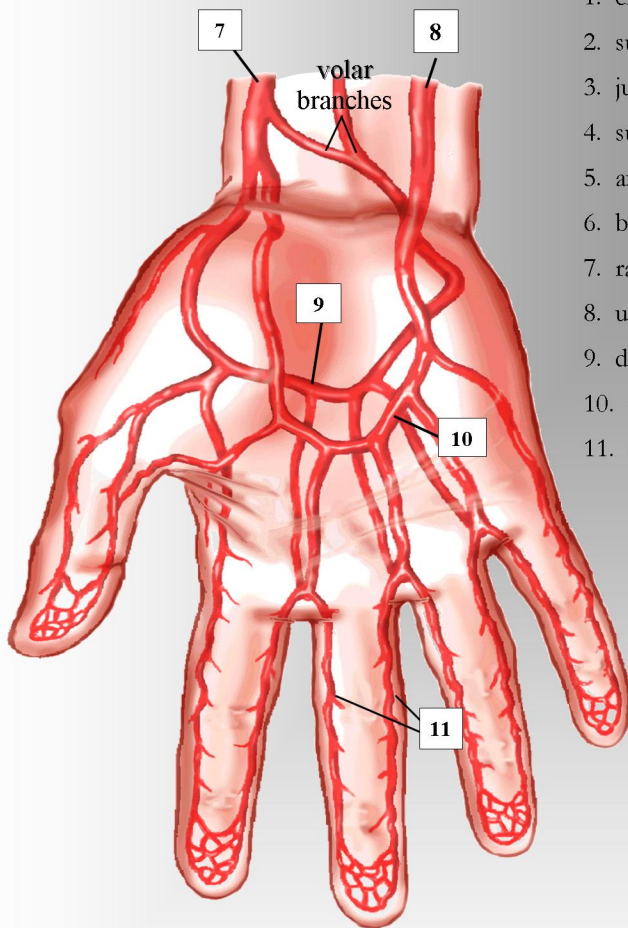
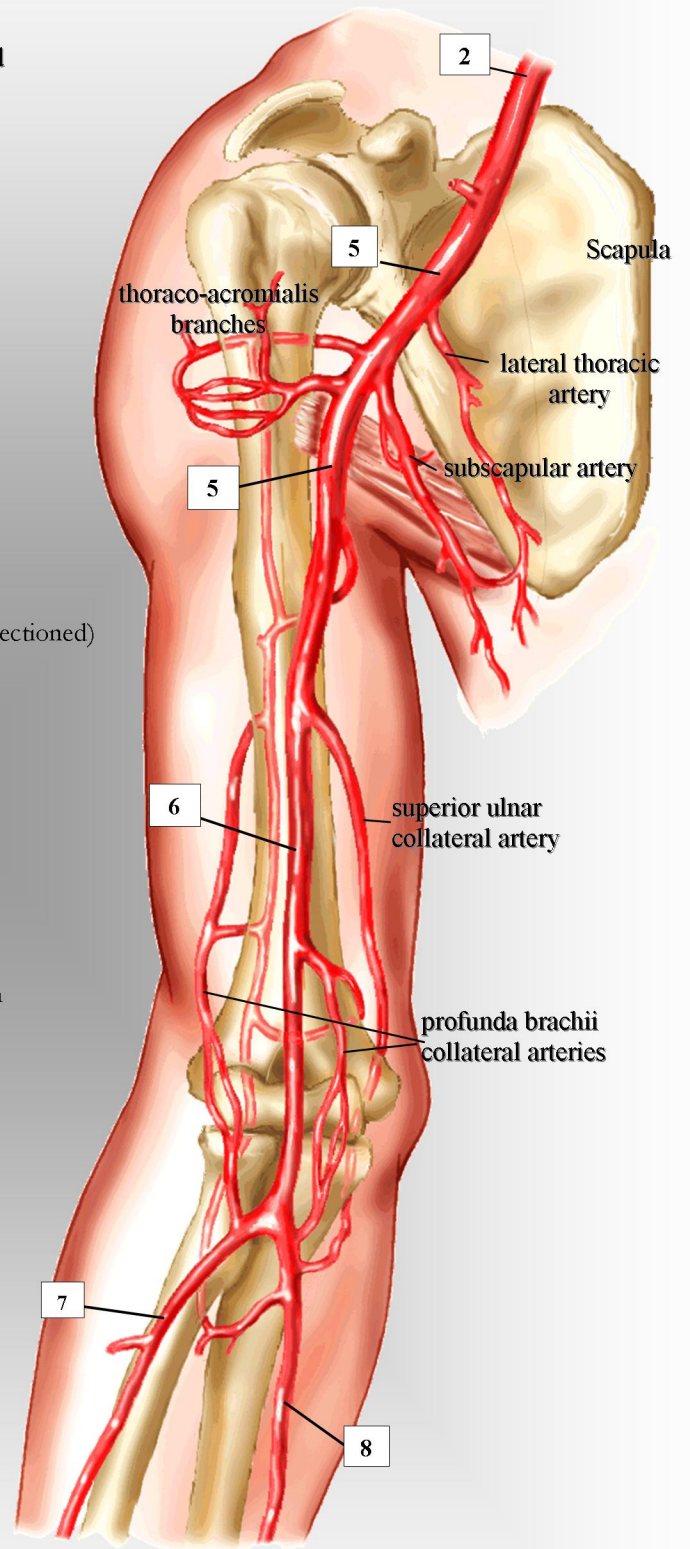
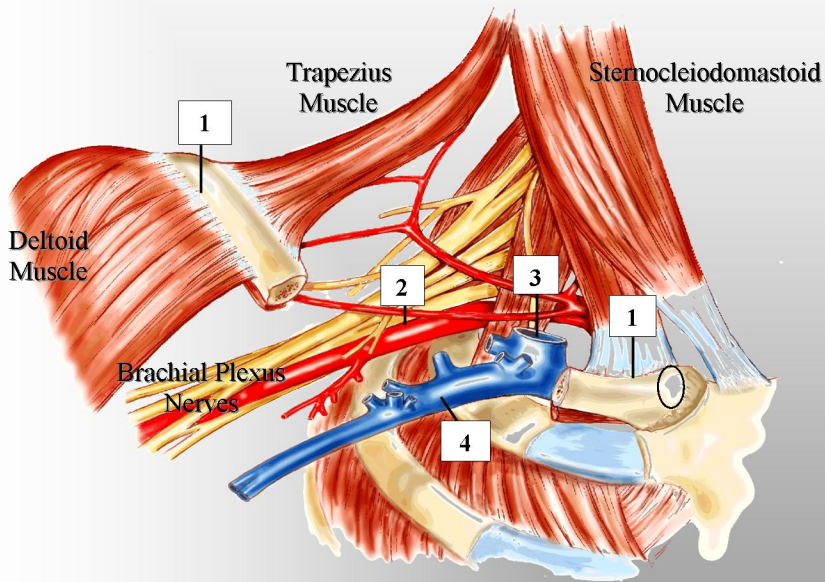


UPPER EXTREMITY ARTERIAL SYSTEM



1. clavicle (shown sectioned)
2. subclavian artery
3. jugular vein
4. subclavian vein
5. axillary artery
6. brachial artery
7. radial artery
8. ulnar artery
9. deep palmar arch
10. median vein
11. digital arteries